Treatment of Xanthelasma Using Hyfrecator

Khoa B. Nguyen[1], Jeremy Man[1]

[1]Kaiser Permanente Los Angeles Medical Center, Los Angeles, CA

KAISER PERMANENTE®

BACKGROUND

- Xanthelasma palpebrae are the most common type of xanthoma and present as periocular yellow papules and plaques.[1]
- Xanthelasma typically do not result in functional impairment but can be cosmetically disfiguring for patients.
- Xanthelasma can be treated with surgical excision or with destructive lasers including CO2, pulsed dye, and Nd:YAG.[2-4]
- However, these methods are associated with considerable post operative downtime, scarring, and financial costs that many patients cannot afford.
- Therefore, this is a considerable knowledge gap regarding cost-effective and minimal-downtime treatments for xanthelasma.

OBJECTIVE

To understand if in-office hyfrecator can be used as an effective and cosmetically sensitive alternative to traditional surgical or destructive methods

CASE

A 69-year-old man presented to the dermatology clinic with complaint of yellow growths at left lower eyelid, left upper eyelid, and right upper eyelid for two years. His past medical history included hyperlipidemia which was well controlled on rosuvastatin 10mg daily. His most recent lipid panel two weeks prior to presentation to dermatology included a total cholesterol of 144, triglyceride of 86, HDL of 56, and LDL of 72. On physical examination, patient had yellow-orange flat plaques at the left lower eyelid, left upper eyelid, and right upper eyelid. A diagnosis of xanthelasma palpebrae was made. Treatment options were presented to the patient including monitor, laser ablation, or surgical excision. Given the extensive downtime and cost associated with surgery or laser treatment, these options were declined. Given the cosmetic disturbance to the patient, he was offered a treatment of electrodesiccation to which he agreed given the low cost and minimal downtime.

RESULTS

Figure 1. Pre-procedure picture showing left upper, left lower, and right upper eyelid xanthelasma

Figure 2. Post-hyfrecator pictures showing resolution of bilateral eyelid xanthelasma

10 weeks post-hyfrecator

5 months post-hyfrecator

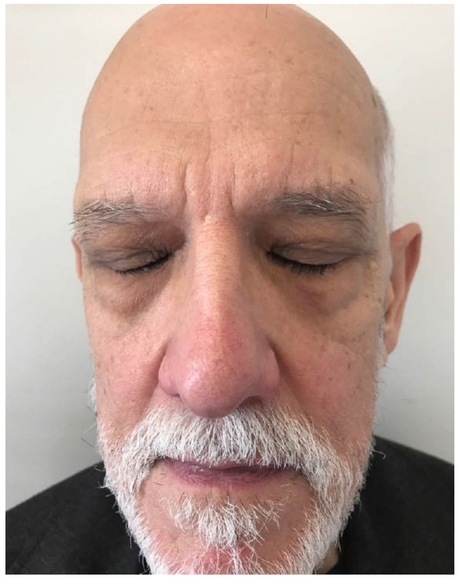

METHOD

With the needle pointed away from the globe, each xanthelasma was anesthetized with 1% lidocaine with 1:100,000 epinephrine for a total of 0.6mL. After each xanthelasma was anesthetized, the hyfrecator was used on setting of high at 4-5 to electrodesiccate the xanthelasma. Care was used to pull the xanthelasma away from the globe and to use short bursts to minimize peripheral tissue destruction. After the superficial layer was destroyed, the superficial layer was curetted away using cue tips soaked in hydrogen peroxide. This cycle was repeated until only a thin layer of xanthelasma could begin to be visualized. Each lesion still had a thin layer of xanthelasma upon completion of the procedure. Patient tolerated the procedure well. Aquaphor was applied and dressing placed. He was instructed to clean with soap and water and apply Vaseline daily. At patient's 10-week return visit, he had excellent cosmetic results. He had complete resolution of the bilateral xanthelasma, with no atrophy, minimal scarring, and minimal pink discoloration.

DISCUSSION

- Low powered, high frequency current has been used to treat superficial skin lesions such as cherry angiomas and venous lakes with minimal damage to surrounding structures.
- The hyfrecator offers a low cost, low downtime, and minimally scarring option compared to surgical excision and ablative lasers for xanthelasma.
- Given that hyfrecators are readily available in most dermatology clinics, we recommend that hyfrecators be considered as a treatment option for xanthelasma.

References

1. Bergman R. The pathogenesis and clinical significance of xanthelasma palpebrarum. *Journal of the American Academy of Dermatology.* 1994;30(2 Pt 1):236-242.
2. Heng JK, Chua SH, Goh CL, Cheng S, Tan V, Tan WP. Treatment of xanthelasma palpebrarum with a 1064-nm, Q-switched Nd:YAG laser. *Journal of the American Academy of Dermatology.* 2017;77(4):728-734.
3. Baroni A. Long-wave plasma radiofrequency ablation for treatment of xanthelasma palpebrarum. *Journal of cosmetic dermatology.* 2019;18(1):121-123.
4. Nguyen AH, Vaudreuil AM, Huerter CJ. Systematic review of laser therapy in xanthelasma palpebrarum. *International journal of dermatology.* 2017;56(3):e47-e55.